

High-Quality Auditory Stimulation for Functional MRI Research: Experience from two studies

by:

Dr. Isabella Mutschler, Department of Psychology, University of Basel, Switzerland; Epilepsy-Center, University Hospital Freiburg, Germany, and

Dr. Tonio Ball, Epilepsy-Center, University Hospital Freiburg, Germany



Dr. Isabella Mutschler



Dr. Tonio Ball

Recently, an increasing number of functional MRI (fMRI) studies have investigated auditory evoked brain responses. Auditory stimulation quality is a crucial issue for such research. Here we report on experience from two recent fMRI studies conducted at 3 T where we used piano pieces for auditory stimulation in healthy human subjects.

In the first study, (Mutschler et al., 2007) we investigated subjects using fMRI, while they were passively listening to simple piano melodies from two conditions: In the 'actively learned melodies' condition subjects learned to play a piece on the piano during a short training session of a maximum of 30 minutes before the fMRI experiment, and in the 'pas-

sively learned melodies' condition subjects listened passively to and were thus familiarized with the piece (Fig. 1). We found increased fMRI responses to actively compared with passively learned melo-



Figure 1: Active/passive melody learning task used in Mutschler et al., 2007. Subjects learned to play two unknown melodies on a piano (actively learned melodies, marked 'A') and were passively familiarized with two other melodies (passively learned melodies, marked 'P'). The assignment to the two learning conditions was balanced across subjects.

odies in the left anterior insula, extending to the left fronto-opercular cortex. The insular cortex may, therefore, play a role in the initial learning phase of action-perception associations.

In the second study (Ball et al., 2007; Mutschler, 2007), we combined fMRI with probabilistic anatomical maps (Amunts et al., 2005) to investigate functional response properties of human amygdala subregions when subjects listened to piano melodies from the Romantic period. We found stronger positive BOLD-signal change in an amygdala-subregion (laterobasal group) where in other mammalian species the majority of subcortical and cortical auditory inputs converge (Fig. 2), pointing to the possibility of a similar sub-regional organization of the amygdala in humans and other mammalian species (cf. Cristinzio, 2007).

In both of these studies slice orientation was sagittal, resulting in significantly lower acoustic noise generated by the imaging gradients. Furthermore,

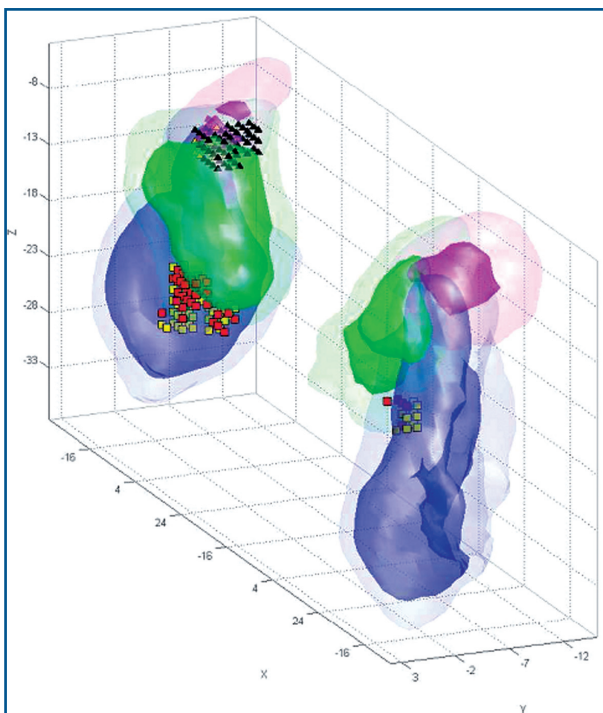


Figure 2: Human amygdala responses to music in probabilistically defined anatomical regions. The volumes with at least 50 % and 80 % probability belong to the three major amygdala subregions: LB = laterobasal group (blue), SF = superficial group (green), and CM = centromedial group (magenta) are rendered with high (for 50 % probability) and low (for 80 % probability) transparency. Voxels with a significant increase in BOLD signal to music presentation are displayed as red or yellow squares ($p < 0.05$, corrected for multiple comparisons, see material and methods for further details in Ball et al., 2007). Voxels with a significant signal decrease are displayed as black or yellow triangles. Anatomical probabilities for red and black responses were 50 % to 60 %, for yellow responses 70 % or above. The majority of significant effects was found in the left amygdala. Positive effects were found in both right and left LB and SF, negative effects were localized in left LB, SF and CM. For visualization, probability maps were smoothed using a spatial filter with a 5 mm isometric Gaussian convolution kernel. For probabilistic assignment, the voxels with significant effects were re-sampled to 1 mm isotropic resolution.

in both fMRI experiments we used the electrostatic NNL AudioSystem for presentation of the auditory stimulus material. After all successful examinations, subjects were asked about the subjective quality of auditory stimulation during the fMRI experiment. Despite the scanner noise, subjects reported good auditory quality. In particular, subjects typically described the sound reproduction as being high in fidelity both for the bass and for the higher range of audible frequencies. Although we have not conducted a quantitative study of different fMRI compatible headphone/sound systems, in our experience auditory stimulation with a high subjective quality is feasible during fMRI experiments.

References:

- Mutschler et al., (2007). A rapid sound-action association effect in human insular cortex. *PLoS ONE*. Feb 28;2(2):e259.
- Ball et al., (2007). Response properties of human amygdala subregions: evidence based on functional MRI combined with probabilistic anatomical maps. *PLoS ONE*, Mar 21;2(3):e307.
- Cristinzio & Vuilleumier, (2007). The role of amygdala in emotional and social functions: implications for temporal lobe epilepsy. *Epileptologie* 24 (2), S. 26-39.
- Mutschler, (2007). The Role of the Human Amygdala and Insular Cortex in Emotional Processing: Investigations using Functional MRI combined with Probabilistic Anatomical Maps. Dissertation at the University of Tübingen (URN: urn:nbn:de:bsz:21-opus-29817, URL: <http://tobias-lib.uni-tuebingen.de/volltexte/2007/2981/>)
- Amunts et al., (2005). Cytoarchitectonic mapping of the human amygdala, hippocampal region and entorhinal cortex: intersubject variability and probability maps. *Anat Embryol*. Dec;210(5-6):343-52.

Multispectral Image Analysis

One of the major strengths of MRI is its unique soft tissue contrast and its ability to measure different properties of the same tissue within one imaging session. Through the variety of pulse sequences available at image acquisition, MRI represents many modalities in its own. In addition to the images generated directly from the MRI system, there are derived images describing perfusion or diffusion properties of the tissue. The increasing number of images available from each patient examination, however, complicates the extraction of valuable diagnostic information across images. Multispectral image analysis has the potential to simplify this problem substantially. In multispectral image

analysis, an unlimited number of images can be combined, and tissue properties across the images can be extracted automatically. As such, multispectral image analysis could assist in the diagnosis of complex diseases, i.e. diagnosis of brain tumors, but also identify disease processes resulting in more subtle tissue changes which are not immediately visible to the human eye.



Yngve Kvinnslund
NIL - Senior Researcher

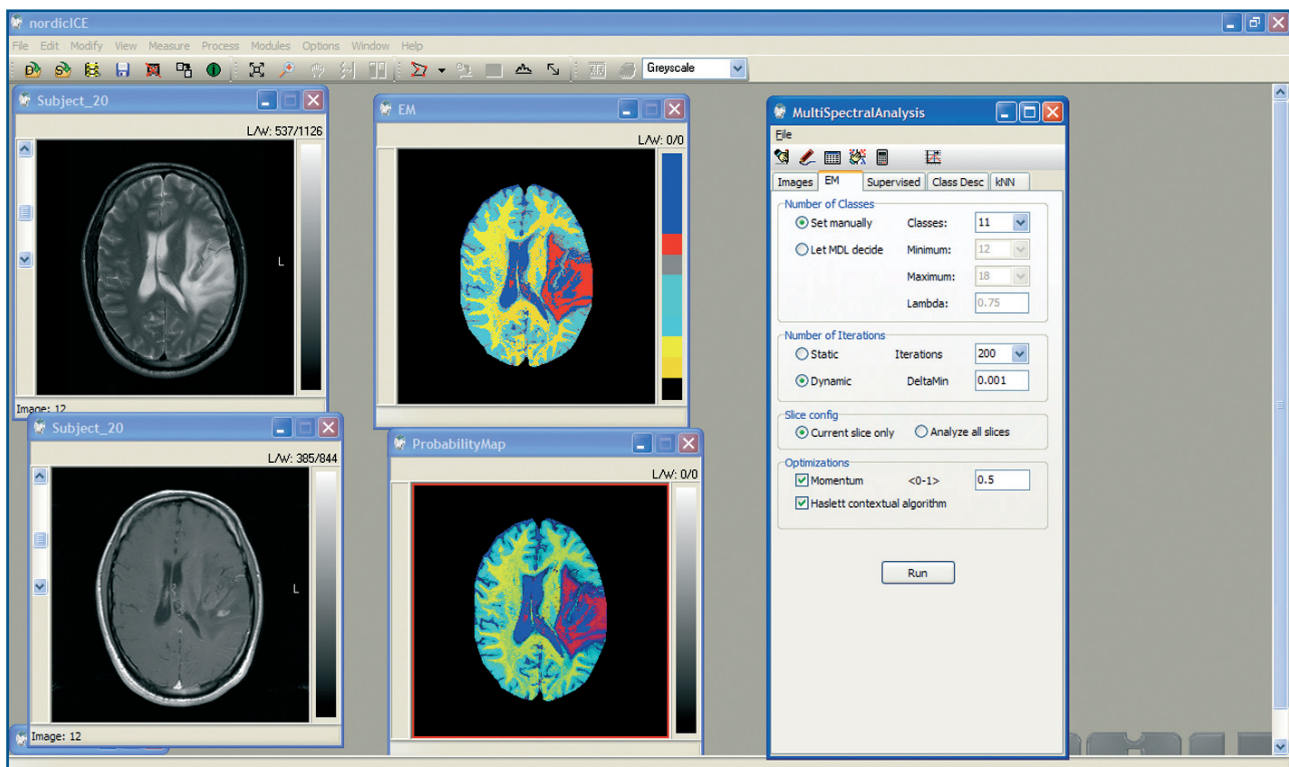


Figure 1: Unsupervised classification using the nordicICE software. The pixels have been divided into CSF (blue), gray (light blue) and white (yellow) matter, tumor (red) and edema (dark blue). In the lower image the pixel colors are a function of the

probabilities of pixels belonging to the different classes, while in the top image the color is set to the color of the class with the highest probability. The panel to the right shows some of the parameters that can be set for the multispectral analysis tool.